
















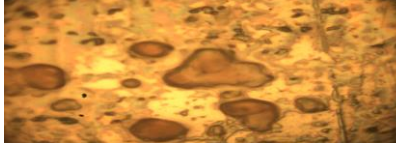











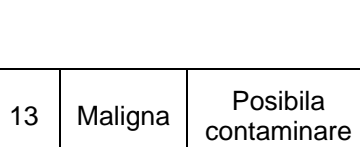
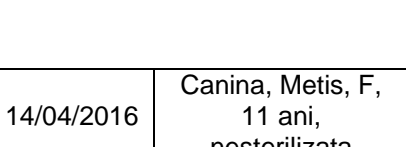
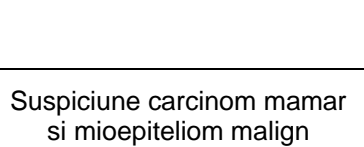
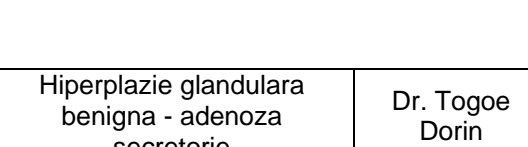





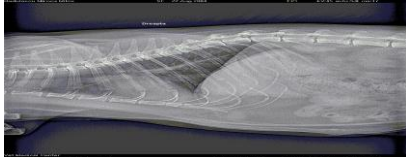




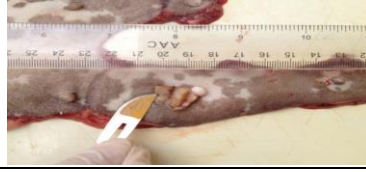
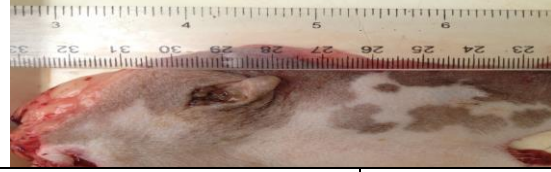


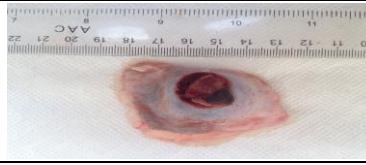
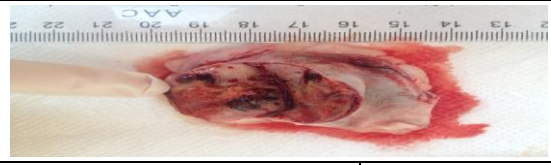





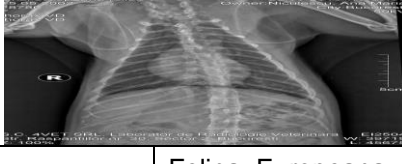














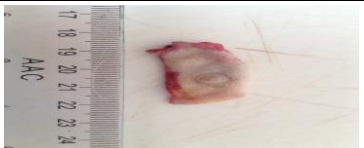
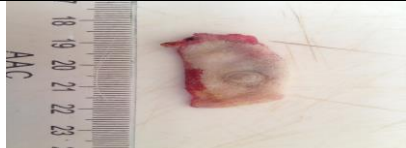








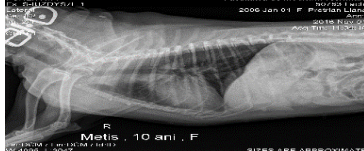
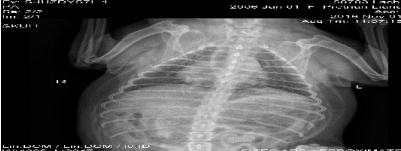

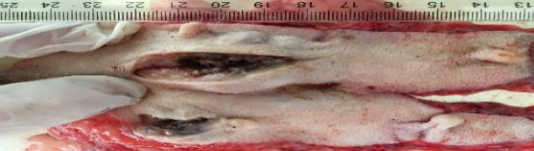




Nr caz	Diagnostic SERS		Data primirii	Date identificare animal	Diagnostic citologic (Prof. Univ. Dr. Militaru Manuella)	Diagnostic histologic (Prof. Univ. Dr. Militaru Manuella)	Chirurg
	Tumora	Margine					
1	Maligna	Posibila contaminare	30/10/2014	Ciobanesc german, F, 3 ani, necastrata	Suspiciune hiperplazie tumorală benignă	Adenoză secretorie (hiperplazie lobulară)	Dr. Togoe Dorin
							
2	Maligna	Posibila contaminare	03/12/2014	Metis, F, 15 ani, nesterilizata	Suspiciune carcinom mamar.	Carcinom mamar tipul tubulo-papilar și tipul solid	Dr. Togoe Dorin
							
3	Maligna	Posibila contaminare	03/12/2014	Cocker, F, 11, ani, nesterilizata	Suspiciune adenocarcinom mamar.	Carcinom mamar tubulo- papilar și hiperplazie lobular (adenoză)	Dr. Togoe Dorin
							
4	Maligna	Posibila contaminare	12/12/2014	Felina, europeana, F, 14 ani, sterilizata	Suspiciune carcinom mamar	Carcinom mamar tipul cribriform	Dr. Vițalaru Alexandru













							
5	Proba lipsa	Margine lipsa	16/12/2014	Felina, europeana, F, 15 ani, sterilizata	Suspiciune carcinom mamar	Carcinom tubulo-papilar	Dr. Togoe Dorin
6	Proba lipsa	Margine lipsa	19/12/2014	Canina, Bulldog, F, 11 ani, sterilizata	Suspiciune carcinom mamar	Carcinom mamar tipul mixt	Dr. Vitalaru Alexandru
7	Proba lipsa	Margine lipsa	19/12/2014	Canina, Golden Retriever, F, 11 ani, nesterilizata	Suspiciune carcinom mamar	Carcinom mamar simplu, tipul tubular cu metastază limfonodală	Dr. Vitalaru Alexandru
8	Maligna	Posibila contaminare	13/01/2015	Canina, Boxer, F, 9,5 ani, nesterilizata	Suspiciune carcinom mamar	Tumoră mixtă benignă	Dr. Togoe Dorin
							
9	Maligna	Posibila contaminare	21/01/2015	Felina, Norvegiană, F, 11 ani, sterilizată	Suspiciune carcinom mamar	Carcinom mamar simplu, tipul cribriform	Dr. Togoe Dorin
-				-		-	





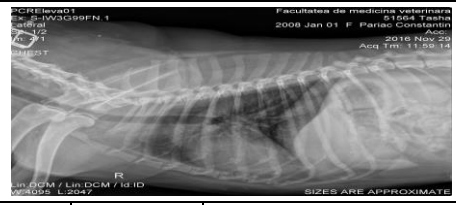






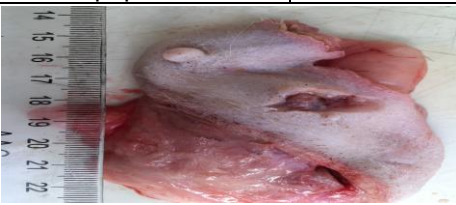



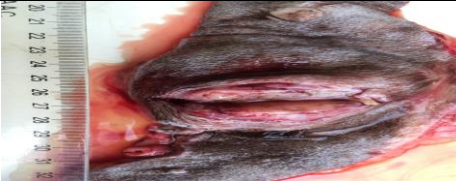
10	Maligna	Posibila contaminare	23/03/2015	Canina, Ciobanesc alsacian, F, 10 ani, nesterilizata	Suspiciune carcinom mamar.	Carcinom mamar mixt.	Dr. Birtoiu Alin
							
11	Proba lipsa	Posibila contaminare	20/11/2015	Canina, Metis, F, 13 ani, nesterilizata	Suspiciune carcinom mamar	Carcinom mamar simplu, tipul lobular, solid si papilifer	Dr. Birtoiu Alin
							
12	Proba lipsa	Margine lipsa	23/03/2016	Canina, Bichon, F, 14 ani, castrată	Suspiciune carcinom mamar.	Carcinom mamar, tipul mixt.	Dr. Birtoiu Alin
							
13	Maligna	Posibila contaminare	14/04/2016	Canina, Metis, F, 11 ani, nesterilizata	Suspiciune carcinom mamar si mioepiteliom malign	Hiperplazie glandulara benigna - adenoza secretorie	Dr. Togoe Dorin
							
14	Neclara	Posibila contaminare	16/09/2016	Felina, Europeana, F, 11 ani,	Suspiciune carcinom mamar simplu	Comedocarcinom mamar	Dr. Vițălaru Alexandru
							






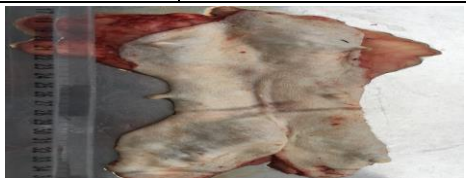





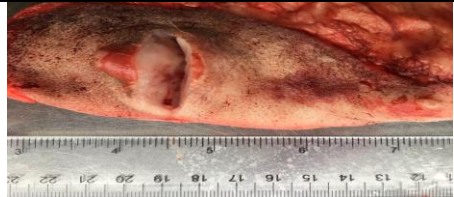




15	Maligna	Posibila contaminare	21/09/2016	Canina, Metis Teckel, F, 8 ani, necastrată	Suspiciune adenocarcinom mamar complex. Suspiciune hiperplazie lobulară mamară.	Carcinom mamar simplu, tipul tubulo-papilar.	Dr. Țogoe Dorin
							
16	Maligna	Posibila contaminare	27/09/2016	Felina, Europeana, F, 17 ani, sterilizata	Suspiciune de carcinom mamar de joasa malignitate.	Carcinom mamar simplu, tipul solid.	Dr. Vitalaru Alexandru
							
17	Maligna	Contaminare	29/09/2016	Canine, Cocker Spaniel, F, 15 ani, sterilizata	Suspiciune adenocarcinom mamar.	Carcinom mamar, tipul mixt cu zone de mioepiteliom malign.	Dr. Țogoe Dorin
							
18	Maligna	Neclara	29/09/2016	Felina, Europeana, F, 14 ani, nesterilizata	Suspiciune carcinom mamar.	Carcinom mamar simplu, tipul cribriform.	Dr. Țogoe Dorin
							
19	Maligna	Contaminare	29/09/2016	Felina, Europeana, F, 9 ani, sterilizata	Suspiciune adenocarcinom mamar.	Carcinom mamar simplu, tipul cribriform.	Dr. Țogoe Dorin
							
















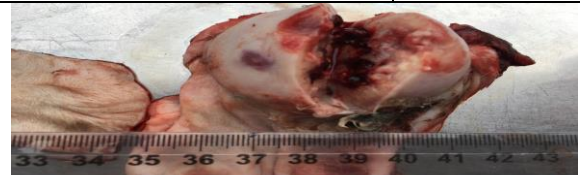
							
20	Maligna	Curata	4/10/2016	Canina, Metis, F, 12 ani, necastrată	Suspiciune adenocarcinom mamar.	Fibroadenom mamar asociat cu un nucleu de carcinom mamar simplu, tipul tubular cu marcanta reactie inflamatorie.	Dr. Vitalaru Alexandru
							
21	Benigna	Neclara	7/10/2016	Canina, Yorkshire, F, 7 ani, sterilizată	Caracteristicile citomorfologice sunt sugestive pentru o tumora epiteliala mamară benignă.	Ectazie ductala asociata cu hiperplazie lobulara mamara (leziuni benigne).	Dr. Diaconescu Alexandru
							
22	Maligna	Posibila contaminare	27/10/2016	Felina, Europeana, F, 10 ani, sterilizata	Suspiciune carcinom mamar.	Carcinom mamar simplu, tipul tubulo-papilar.	Dr. Diaconescu Alexandru
							
23	Maligna	Posibila contaminare	1/11/2016	Canina, Metis, F, 10 ani, necastrată	Suspiciune adenocarcinom mamar.	Carcinom mamar, tipul mixt.	Dr. Țogoe Dorin







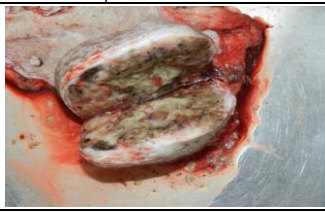




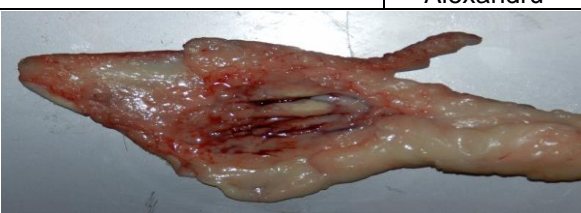
							
24	Maligna	Posibila contaminare	09/11/2016	Cocker Spaniel, F, 12 ani, castrată	Suspiciune carcinom mamar de joasa malignitate.	Carcinom mamar simplu, tipul solid.	Dr. Diaconescu Alexandru
							








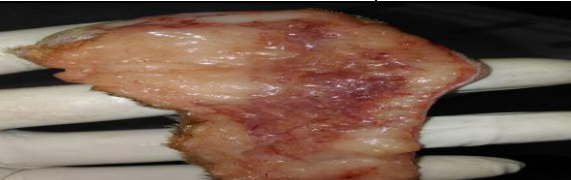








Nr caz	Diagnostic SERS		Data primirii	Date identificare animal	Diagnostic citologic (Prof. Univ. Dr. Militaru Manuella)	Diagnostic histologic (Prof. Univ. Dr. Militaru Manuella)	Chirurg
	Tumora	Margine					
25	Maligna	Posibila contaminare	15/11/2016	Felina Europeana, F, 15 ani, castrată	Suspiciune carcinom mamar.	Carcinom mamar simplu, tipul tubulopapilar.	Dr. Diaconescu Alexandru
 <p>PCREleva01 Ex: SFTYGAJ1.1 Lateral Se: 2/2 m: 2/1 Acq: 2016 Oct 06 Acq Tm: 11:00:20 CHEST R Europeana, 15 ani, F SIZES ARE APPROXIMATE</p>		 <p>PCREleva01 Ex: SFTYGAJ1.1 Lateral Se: 2/2 m: 2/1 Acq: 2016 Oct 06 Acq Tm: 11:03:06 SKULL R L SIZES ARE APPROXIMATE</p>					
26	Maligna	Posibila contaminare	23/11/2016	Felina Birmaneza, F, 15 ani, necastrată	Suspiciune adenocarcinom mamar.	Comedocarcinom mamar.	Dr. Vitalaru Alexandru
 <p>PCREleva01 Ex: SFTYGAJ1.1 Lateral Se: 1/1 m: 2/1 Acq: 2016 Nov 09 Acq Tm: 12:07:59 CHEST R Birmaneza, F SIZES ARE APPROXIMATE</p>							
27	Maligna	Curata	05/12/2016	Felina Europeana, F, 13 ani, castrată	Suspiciune carcinom mamar.	Carcinom mamar, tipul cribriform.	Dr. Vitalaru Alexandru
							

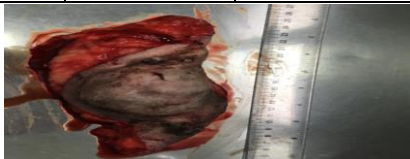
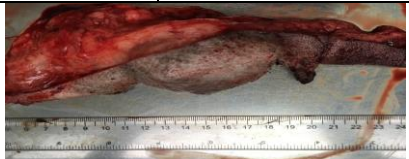




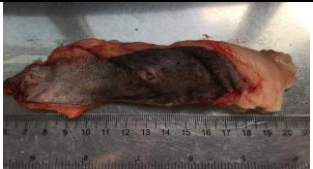







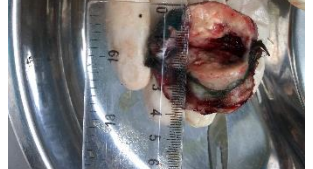
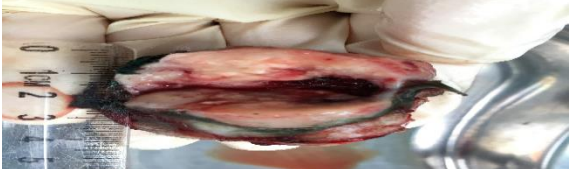
28	Maligna	Curata	06/12/2016	Brac German, F, 12 ani, castrată	Carcinom mamar simplu (M2) si carcinom scvamocelular (M3-M4).	M2 - carcinom mamar, tipul mixt; M3 – M4 - carcinom scvamocelular.	Dr. Togoe Dorin
							
29	Maligna	Posibila contaminare	07/12/2016	Canina Samoyed, F, 8 ani, necastrată	Carcinom mamar simplu.	Carcinom mamar anaplastic.	Dr. Togoe Dorin
							
30	Maligna	Curata	09/12/2016	Canina Metis, F, 7 ani, castrată	Suspiciune carcinom mamar mixt.	Carcinom mamar simplu, tipul tubulopapilar.	Dr. Diaconescu Alexandru
							
31	Maligna	Margine lipsa	09/12/2016	Canina Field Spaniel, F, 14 ani, necastrată	Suspiciune mioepiteliom malign.	Mioepiteliom malign.	Dr. Vitalaru Alexandru
							




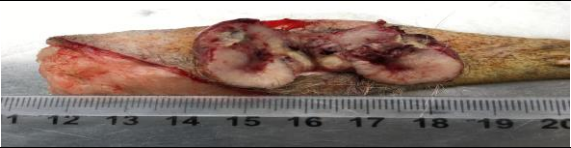




32	Maligna	Margine lipsa	16/12/2016	Canina Caniche, F, 12ani, castrată	Nu s-a realizat.	Carcinom mamar, tipul secretor.	Dr. Togoe Dorin
							
33	Maligna	Posibila contaminare	08.02.2017	Canina, Husky, F, 9 ani, Castrata	Tumoră epiteliala maligna-adenocarcinoma mamar. (Georgeta Dinescu)	Carcinom mamar de tip complex.	Dr. Diaconescu Alexandru
							
33 - 1	Benigna	Curata	19.12.2016	Canina, Shar-Pei, F, 7 ani si 10 luni, Castrata	Nu s-a realizat.	Tumora histiocitara.	Dr. Diaconescu Alexandru
							
34	Maligna	1, 2 Posibila contaminare; (2 recidiva)	21.12.2016	Canina, Caniche, F, 7 ani si 9 luni, Necastrată	Nu s-a realizat.	Carcinom mamar, tipul complex.	Dr. Diaconescu Alexandru
							

Nr caz	Diagnostic SERS		Data primirii	Date identificare animal	Diagnostic citologic (Prof. Univ. Dr. Militaru Manuella)	Diagnostic histologic (Prof. Univ. Dr. Militaru Manuella)	Chirurg
	Tumora	Margine					
35	Maligna	Posibila contaminare	06.01.2017	Felina, Birmaneza, F, 14 ani, Castrată.	Nu s-a realizat	Carcinom mamar simplu, tipul solid.	Dr. Diaconescu Alexandru
							
36	Maligna	Posibila contaminare	30.01.2017	Canină, Labrador, F, 13 ani, Necastrată	Suspiciune adenocarcinom mamar.	Carcinom tipul tubulo-papilar.	Dr. Vițălaru Alexandru
							
37	Maligna	Posibila contaminare	01.02.2017	Canina, Peckinez, F, 8 ani, Necastrată	Tumură epitelială malignă – adenocarcinom mamar.	Carcinom micropapilar invaziv	Dr. Diaconescu Alexandru
							
38	Benigna, lant stang; Maligna lant drept	Curata	02.02.2017	Felina, Europeana, F, 15 ani, Necastrată	Tumură epitelială malignă – adenocarcinom mamar.	Comedocarcinom mamar.	Dr. Vitalaru Alexandru
							

39	Maligna	Curata	07.02.2017	Felină, Europeană, F, 7 ani, Castrată	Formațiune tumorală benignă – adenom de glandă mamară.	Hiperplazie lobulară de tip secretor și ectazie ductală cu produs eozinofilic intraluminal.	Dr. Diaconescu Alexandru
							
39 - 1	Maligna	Posibila contaminare	10.02.2017	Canină, Ciobănesc German, F, 7 ani, Necastrată	-	-	Dr. Bîrțoiu Alin
-		-		-		-	
40	Maligna	Posibila contaminare	03.03.2017	Canină, Bichon, F, 12 ani, Castrată	Adenocarcinom de glandă mamară cu posibilă diferențiere scvamoasă.	Carcinom mamar simplu, tipul tubulo-papilar și tipul solid.	Dr. Vitalaru Alexandru
							
41	Maligna	Posibila contaminare	16.03.2017	Felină, Birmaneză, F, 12 ani, Necastrată	Adenom de glandă mamară.	Carcinomului mamar de tip cribriform.	Dr. Diaconescu Alexandru
							

42	Maligna	Posibila contaminare	05.04.2017	Canină, Metis, F, 13 ani, Castrată	Hiperplazie reactiva limfonodală.	Lipom.	Dr. Țogoe Dorin
							
43	Maligna	Posibila contaminare	03.05.2017	Felină, Europeană, F, 14 ani, Castrată	-	Adenomul intraductal papilifer	Dr. Diaconescu Alexandru
							
44	Maligna	Posibila contaminare	08.05.2017	Canină, Ciobănesc german, M, 13 ani, Castrat	-	Adenocarcinom mamar simplu tipul tubulo-papilar cu zone cribriforme	Dr. Vițălaru Alexandru
							
45	Maligna	Posibila contaminare	09.05.2017	Felină, Birmaneză, F, 10 ani, -	-	Adenocarcinom mamar simplu tipul tubulo-papilar și solid	Dr. Vițălaru Alexandru
							

Nr caz	Diagnostic SERS		Data primirii	Date identificare animal	Diagnostic citologic (Prof. Univ. Dr. Militaru Manuella)	Diagnostic histologic (Prof. Univ. Dr. Militaru Manuella)	Chirurg
	Tumora	Margine					
46	Maligna	Posibila contaminare	26.05.2017	Canina, Ciobanesc german, F, 10 ani, Necastrat	-	Carcinom, tipul complex.	Dr. Țogoe Dorin
							
47	Maligna	Posibila contaminare	29.06.2017	Felina, Europeana, F, 9 ani, Castrata	-	Carcinom simplu, tipul tubular.	Dr. Diaconescu Alexandru
							
48	Maligna	Posibila contaminare	04.07.2017	Canina, German Shorthaired Pointer, F, 9 Ani, Necastrata	-	Carcinom simplu, tipul tubulo-papilar și metastază limfonodală.	Dr. Țogoe Dorin
							
49	Maligna	Posibila contaminare	04.07.2017	Felina, Europeana, F, 15 ani, Castrata	-	Carcinom mamar simplu, tipul solid.	Dr. Diaconescu Alexandru
							

50	Maligna	Posibila contaminare	25.07.2017	Canina Metis, F, 10 ani, Sterilizată	-	-	Dr. Țogoe Dorin
							
51	Neclar	Neclar	07.08.2017	Canina Parson Jack Russel, F, 9 ani, Nesterilizată	-	Fibroadenom	Dr. Vițălaru Alexandru
							
52	Maligna		04.09.2017	Canina Metis, F, 11 ani, Nesterilizată	-	-	Dr. Țogoe Dorin
